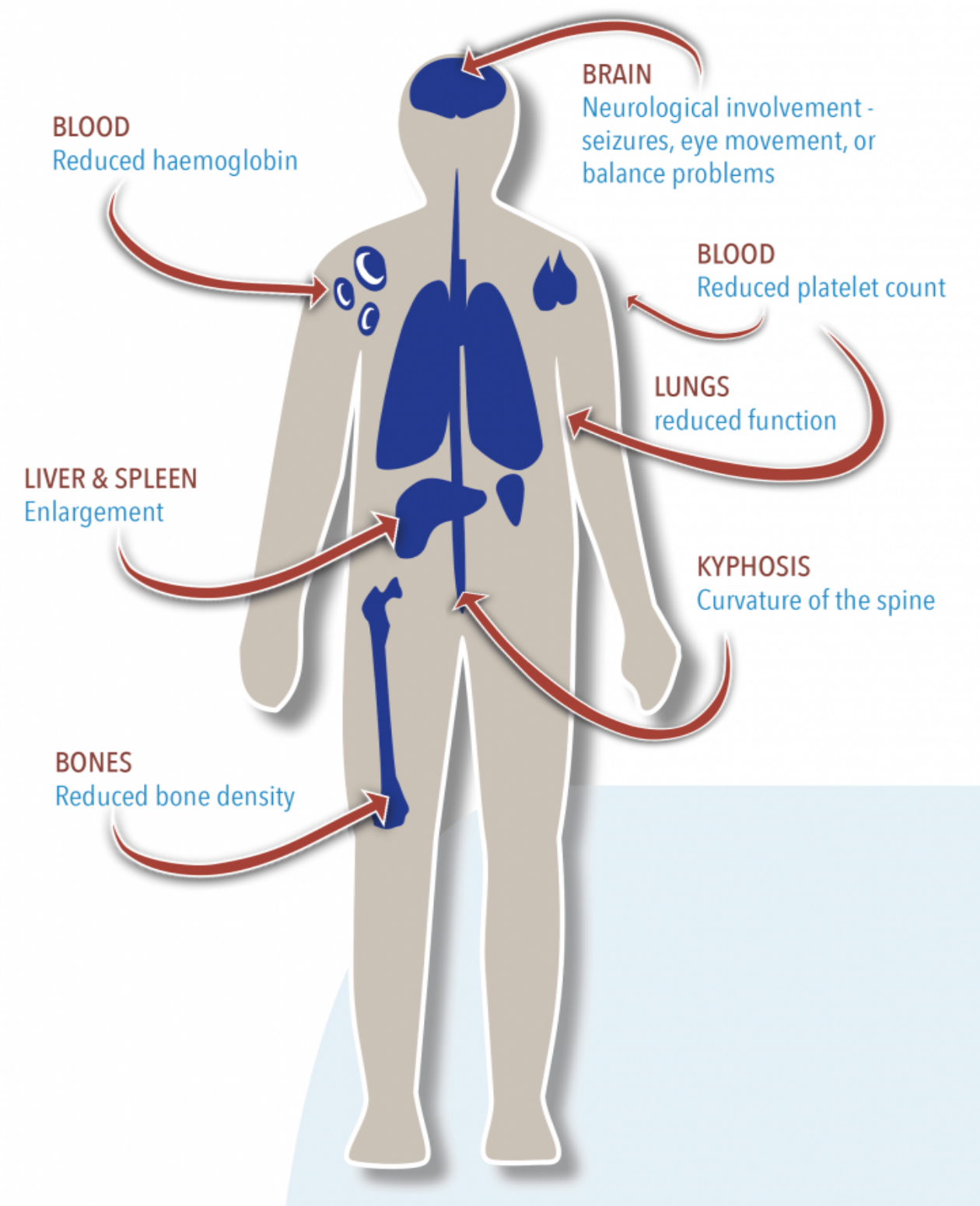


Ashley Perez BS¹, Matthew Morris BA², David Gilbert BS¹, Karina Kowalski MD³, Garima Garg MD^{1,3}

1 Case Western Reserve University School of Medicine, 2 Heritage College of Osteopathic Medicine, 3 MetroHealth Medical Center, Cleveland, Ohio

Introduction

- GD is an autosomal recessive lysosomal storage disorder caused by a GBA1 gene mutation.
- This results in glucocerebrosidase deficiency and accumulation of glucocerebroside in various tissues, including the spleen, liver, and bone marrow (1).
- GD is classified into three types: non-neuropathic (Type 1), acute neuropathic (Type 2), and chronic neuropathic (Type 3).
- Type 3C is a Type 3 variant, characterized by cardiovascular calcifications and other systemic involvement (2).
- Though less common, neuropsychiatric manifestations can occur in patients with Type 3 GD, ranging from cognitive impairments to more severe psychiatric symptoms, including psychosis (3).



<https://gaucheralliance.org/type-3/>

Case Presentation

A 26-year-old male with a past medical history of Type 3C GD, drug resistant epilepsy, autism, HOCM, chronic non-hepatic hyperammonemia from N-acetylglutamate synthase deficiency, pulmonary HTN, asthma, DVT, and conduct disorder presented to the ED in October 2022 for paranoia, somatic and persecutory delusions, visual hallucinations, and aggressive behavior. The patient's mother (primary caretaker) reported that these symptoms began after a recent hospitalization (July 2022) and worsened since then. The patient reported his mother stole a taser and gun from him and was trying to poison him, which prompted him to bite her and break glass to harm her. During hospitalization, the patient remained paranoid, reporting people were trying to shoot and poison him. At this time, the patient was on a high dose of Seroquel, which was switched to Prolixin, and the patient improved. It appeared these symptoms were likely not due to a primary psychotic disorder, but rather a progression of the patient's neurodevelopmental disorder.

References

1. Sidransky, E., & Lopez, G. (2012). The link between the GBA gene and parkinsonism. *The Lancet Neurology*, 11(11), 986-998.
2. Rosenbloom, B. E., & Weinreb, N. J. (2013). Gaucher disease: a comprehensive review. *Critical Reviews in Oncology/Hematology*, 87(3), 146-179
3. Biegstraaten M, Wesnes KA, Luzy C, Petakov M, Mrcic M, Niederau C, Giraldo P, Hughes D, Mehta A, Mengel KE, Hollak CE, Maródi L, van Schaik IN. The cognitive profile of type 1 Gaucher disease patients. *J Inher Metab Dis*. 2012 Nov;35(6):1093-9. doi: 10.1007/s10545-012-9460-7. Epub 2012 Feb 21. PMID: 22350617; PMCID: PMC3470680.
4. Stirnemann, J., Belmatoug, N., Camou, F., & Serratrice, C. (2017). A review of Gaucher disease pathophysiology, clinical presentation and treatments. *International Journal of Molecular Sciences*, 18(2), 441.

Discussion

- Neuropsychiatric manifestations in GD are increasingly recognized but remain underappreciated.
- The pathophysiology is thought to involve accumulation of glucocerebroside in the central nervous system, causing neuroinflammation, neuronal loss, and synaptic dysfunction.
- This can manifest as a spectrum of cognitive, motor, and psychiatric symptoms, including psychosis (3).
- The distinction between primary psychiatric disorders and neuropsychiatric manifestations of GD is crucial for management.
- In this case, the patient's psychosis was hypothesized to be directly related to progression of his GD.
- Response to antipsychotic treatment supports this hypothesis, although further research is needed to understand the precise mechanisms (4).
- This case underscores the importance of considering neuropsychiatric manifestations of GD, particularly in patients with Type 3.